

## A dangerous duo: spontaneous pneumomediastinum and venous thromboembolism at presentation in a patient with COVID-19 pneumonia

Sabina Nasirova

Nargiz Mughanlinskaya

Orighomisan Pessu

Arshdeep Brar

Follow this and additional works at: <https://scholarlycommons.gbmc.org/jchimp>



Part of the [Medicine and Health Sciences Commons](#)

---

# A Dangerous Duo: Spontaneous Pneumomediastinum and Venous Thromboembolism at Presentation in a Patient with COVID-19 Pneumonia

Received - March 25, 2021; Accepted - September 30, 2021

Sabina Nasirova\*, Nargiz Mughanlinskaya, Orighomisan Pessu, Arshdeep Brar

Department of Medicine, Luminis Health Anne Arundel Medical Center, Annapolis, MD, USA

## Abstract

**Background:** Coronavirus disease 2019 (Covid-19) is associated with spontaneous pneumomediastinum (SPM) predominantly in those after positive pressure ventilation (PPV) support. Additionally, many cases of venous thromboembolism (VTE) in COVID-19 patients were described. Our case is the first to describe SPM and VTE present on admission in a patient with Covid –19 pneumonia.

**Case report:** A 53-year-old man presented to the hospital with escalating dyspnea. Two weeks prior to this visit, he had been evaluated in an ambulatory setting and was started on antibiotics and systemic steroids. In the hospital, this patient was found to be in acute hypoxic respiratory failure and was placed on noninvasive PPV. Diagnosis of severe acute respiratory syndrome coronavirus 2 (SARS-CoV-2) was confirmed by reverse transcriptase-polymerase chain reaction (RT-PCR) test from nasopharyngeal swab specimen. Chest computed tomography (CT) scan revealed multi-lobar pulmonary emboli (PE) and subcutaneous emphysema with pneumomediastinum. The patient was managed conservatively. He never required closed invasive mechanical ventilation. Subsequent serial imaging displayed the resolution of SPM.

**Conclusion:** The association between VTE and COVID-19 has been established. This report brings attention to SPM as an additional important complication of COVID-19, even in patients without pre-existing predisposing pathology or exposure to PPV.

**Keywords:** Spontaneous pneumomediastinum, Coronavirus disease 2019, Covid-19 pneumonia, Severe acute respiratory syndrome coronavirus 2, Pulmonary embolism, Venous thromboembolism

## 1. Background

Coronavirus disease 2019 (Covid-19) is a worldwide pandemic of predominantly respiratory illness that is caused by severe acute respiratory syndrome coronavirus 2 (SARS-CoV-2).<sup>1</sup>

SARS-Cov-2 is a positive strand RNA virus that belongs to a broad beta coronavirus family that can cause high variability of symptoms in humans from a “common cold” type presentation to acute respiratory distress syndrome (ARDS).<sup>2</sup> A novel coronavirus outbreak began in China, Wuhan, in late November 2019, with the first USA case documented in January 2020. So far, more than 90 million confirmed cases have been reported globally.<sup>3,4</sup>

As the Covid-19 pandemic continues to evolve, the medical society has expanded understanding of the plethora of Covid-19 associated comorbidities and effective therapeutic interventions.

There are no specific antiviral medications recommended for treatment of COVID-19 in the outpatient setting. After the results of the Adaptive Covid-19 Treatment Trial were shared with the public in May 2020, remdesivir became the first antiviral agent to be approved by FDA, initially for an emergency use authorization with subsequent full endorsement and has been used since in the inpatient setting.<sup>5,6</sup> In addition, the Randomised Evaluation of Covid-19 Therapy trial reported that dexamethasone reduces mortality in patients

\* Corresponding author at: Department of Medicine, Luminis Health Anne Arundel Medical Center, 2003 Medical Parkway, Suite 350, Annapolis, MD, 21401, USA.  
E-mail address: [snasirova@aahs.org](mailto:snasirova@aahs.org) (S. Nasirova).

requiring oxygen supplementation, with the strongest benefit in the mechanically ventilated group.<sup>7</sup>

The patients with underlying health issues are more susceptible to respiratory complications, such as pneumonia, ARDS, pulmonary embolism (PE), as well as non-respiratory complications, like septic shock, hypercoagulable state, renal failure, neurologic amongst other conditions.<sup>8,9</sup>

Among uncommon, yet important, complications is pneumomediastinum (PM). In the majority of the cases, barotrauma due to positive pressure ventilation (PPV) has been recognized as one of the main provoking factors of development of PM in the COVID-19 patients.<sup>10–23</sup> Few COVID-19 cases complicated with SPM have been reported in those without preceding exposure to PPV.<sup>14,24–47</sup> These cases suggest the emerging relation between COVID-19 and SPM even in patients without any pre-existing conditions or prior positive pressure oxygen supplementation.

Thus far, only one case of COVID-19 complicated simultaneously by subcutaneous emphysema, VTE and PM was found in literature and described a patient who developed PM only after several days of closed mechanical ventilation and also demonstrated a thrombus in the right jugular vein extending to the superior vena cava and into the right brachial vein.<sup>48</sup> Another recent case report showed development of PM on the 19th day of hospitalization in a patient with COVID-19 and PE who was not intubated and without known chest trauma.<sup>49</sup>

The aim of the report is therefore, to describe a 53-year-old man who presented with SPM and extensive PE and DVT in the setting of severe COVID-19 pneumonia. To our knowledge, this is the first case report where these complications were present simultaneously on admission.

## 2. Case presentation

A 53-year-old man with no known relevant past medical history reports symptoms started two weeks ago with nasal congestion and dry cough. At that time, the patient was diagnosed with sinusitis by his primary care provider during telemedicine visit and started on oral azithromycin.

A few days after that, the patient developed dyspnea and was subsequently evaluated at a local urgent care facility. Chest X-ray was suggestive of pneumonia, and the patient was started on oral doxycycline, systemic steroids and short acting beta agonist inhaler. Six days later, the patient returned to the urgent care facility as his condition had worsened, with now even minimal exertion

### Abbreviations

ARDS	Acute respiratory distress syndrome
Covid –19	Coronavirus disease 2019
CT	Computed tomography
DVT	Deep venous thrombosis
ED	Emergency department
FDA	Food and Drug Administration
FiO <sub>2</sub>	Fractional inspired oxygen
HFNC	High flow nasal cannula
LDH	Lactate dehydrogenase
PE	Pulmonary embolism
PM	Pneumomediastinum
PPV	Positive pressure ventilation
RT- PCR	Reverse transcriptase polymerase chain reaction
SARS-CoV-2	Severe acute respiratory syndrome coronavirus 2
SPM	Spontaneous pneumomediastinum
SpO <sub>2</sub>	Oxygen saturation
VTE	Venous thromboembolism

resulting in severe dyspnea. The patient's oxygen saturation (SpO<sub>2</sub>) was found to be 79% while breathing ambient air and he was sent to this hospital by ambulance. The patient was seen in the ED with escalating dyspnea.

Upon arrival, the patient's vital signs were as following: temperature (T) 37 °C, blood pressure (BP) 102/69 mmHg, heart rate (HR) 114 beats per minute (bpm), respiration rate 24 breaths per minute, SpO<sub>2</sub> 85% while receiving 4 L of supplemental oxygen via nasal cannula. The patient was in respiratory distress and was using accessory breathing muscles. Crackles were heard diffusely upon lung auscultation. There was a crepitus around the neck predominantly on the right side. There was asymmetric mid-calf edema greater on the right side. The rest of the physical exam was unremarkable.

Pertinent laboratory results were as following: D dimer 11.57 ng/ml (reference <0.50), CRP 2.080 mg/dl (reference 0.000–1.000 mg/dL), Ferritin 655 ng/ml (reference 10.0–291.0 ng/ml), LDH 341 U/L (reference 20–300 U/L), PT 14.6 s (reference 11.4–13.8 s), INR 1.2 (reference 1.0–1.0), and HgA1C 13.4% (reference <6.5%). Venous blood gas values: PH 7.43 (reference 7.35–7.45), PCO<sub>2</sub> 43.9 mmHg (reference 35.0–45.0 mmHg), PO<sub>2</sub> 26.7 mmHg (reference 90.0–100.0 mmHg), HCO<sub>3</sub> 29.3 mmol/L (reference 22.0–28.0 mmol/L). The rest of the blood work results are presented in the [Table 1](#). Due to escalating hypoxia the patient was transitioned to high flow nasal cannula (HFNC) with fractional inspired oxygen (FiO<sub>2</sub>) 70% and flow rate 30 L/min. CT with intravenous contrast revealed extensive multi-lobar pulmonary emboli, multifocal areas of consolidation, ground

Table 1. Laboratory results on admission.

BMP			Reference	CBC			Reference
		Units				Units	
Sodium	131	mmol/L	135–146	WBC	10.79	$\times 10^3/\mu\text{L}$	4.80–10.80
Potassium	4.8	mmol/L	3.2–5.0	RBC	6.13	$\times 10^6/\mu\text{L}$	4.10–5.30
Chloride	93	mmol/L	95–112	Hemoglobin	17.3	g/dL	12–16
CO <sub>2</sub>	33	mmol/L	18–32	Hematocrit	51.7	%	37–47
BUN	10	mg/dL	5.0–25	MCV	84.3	fL	81–99
Creatinine	0.9	mg/dL	0.5–1.5	MCH	28.2	pg	28.0–32.0
Anion Gap	5	mmol/L	5.0–2.0	MCHC	33.5	g/dL	32.0–36.0
Glucose	408	mg/dL	65–140	RDW	12.4	%	11.8–15.5
Magnesium	2.2	mg/dL	1.7–2.2	Platelet	352	$\times 10^3/\mu\text{L}$	150–350
Calcium	8.3	mg/dL	8.1–10.2	MPV	9.8	fL	9.5–13.3
Total protein	6.7	g/dL	6.4–8.2				
Albumin	2.6	g/dL	3.2–5.0				

glass opacities, hilar lymphadenopathy, and extensive subcutaneous emphysema extending to the skull base throughout the neck as well as along the right greater than left chest wall and pneumomediastinum without pneumothorax. There was no radiographic evidence of esophageal perforation [Fig. 1]. Lower extremities venous duplex ultrasound noted thrombi in the right and left peroneal veins.

Diagnosis of SARS-CoV-2 was confirmed by the BD Veritor™ System for Rapid Detection of SARS-CoV2 antigen test (Becton Dickinson, New Jersey, USA) from nasopharyngeal swab specimen. The radiographic findings were consistent with COVID-19 pneumonia as well.

Multidisciplinary approach with a team of thoracic surgery, infectious disease, and

pulmonology services commenced. No invasive interventions were recommended, and close monitoring and serial chest X-rays were suggested. He was started on anticoagulation for a provoked PE treatment, along with intravenous remdesivir and oral dexamethasone. He completed the five-day course of remdesivir and ten-day course of dexamethasone. He also received intravenous antibiotics for mediastinitis prophylaxis as recommended by infectious disease consultants. The patient remained dependent on HFNC for 10 days and then transitioned to ambient air. The serial imaging demonstrated gradual resolution of subcutaneous emphysema and pneumomediastinum. After 12 days of hospitalization, the patient was

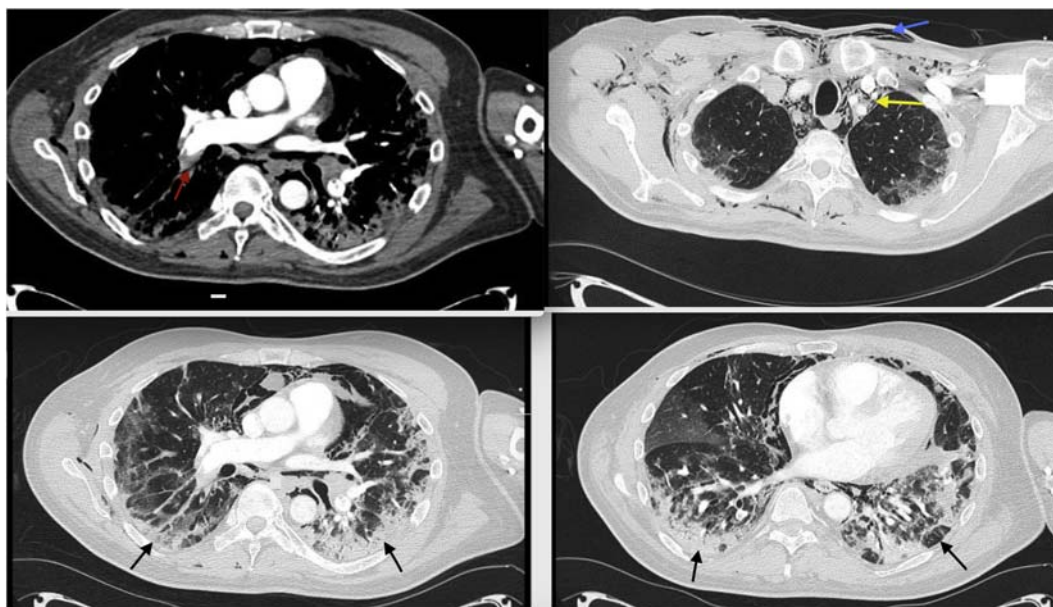


Fig. 1. Chest computed tomography angiography scan. Black arrows: bilateral patchy areas of ground glass opacification and consolidation. Red arrow: pulmonary emboli. Blue arrow: extensive subcutaneous emphysema. Yellow arrow: the air in the mediastinum.

discharged home with appropriate post-acute care follow up plan in place.

### 3. Discussion

SPM is described as accumulation of gas in the mediastinum without precipitating trauma.<sup>50</sup> The most common causes of pneumomediastinum in non Covid-19 patients are esophageal perforation, cough, Valsalva maneuver, perforated hollow viscus, and infection. These can lead to increased pressure in thoracic cavity and leakage of air.<sup>51</sup> The pathogenesis of SPM in Covid-19 patients is unclear. Autopsy findings in Covid-19 patients described diffuse alveolar damage with lymphoplasmacytic inflammation and areas of fibrin thrombus, which support the theory of lung parenchymal injury as the leading cause of SPM and PT.<sup>44</sup> Also, development of SPM could likely be explained by diffuse alveolar damage in the setting of hyperinflammatory process, subsequent alveoli collapse and rupture.<sup>52</sup> Increased pressure in alveoli and, as a result, sufficient pressure gradient between alveoli and surrounding tissue can cause alveolar rupture. The air from ruptured alveoli dissects through the bronchoalveolar plane and vascular sheath into the mediastinum and gets trapped there due to higher negative pressure. The accumulated air can track to the pleural space, pericardium, retroperitoneal space or soft tissues of the neck and chest and cause pneumopericardium, pneumothorax, or subcutaneous emphysema via communicative route.<sup>53</sup>

Few COVID-19 cases complicated with spontaneous pneumomediastinum have been reported without preceding chest trauma or barotrauma from PPV.<sup>14,24–47</sup> In our patient, radiographic evidence of SMP preceded initiation of noninvasive positive pressure oxygen supplementation. Further, our patient did not report common predisposing factors for pneumomediastinum such as smoking, emphysema, asthma, cocaine abuse, vomiting, forceful cough, prior surgery, iatrogenic or external trauma.

PE and deep venous thrombosis (DVT) are well described phenomena in Covid-19 patients.<sup>54–58</sup> Our patient was also found to have extensive PE and thrombosis of right and left peroneal veins.

To our knowledge, this is the first case report where PE, DVT, and SMP with subcutaneous emphysema presented simultaneously in a patient with COVID-19 pneumonia and who did not have any other identifiable risk factors for either of the presenting diagnoses.

### 4. Conclusion

The literature review provides crucial insights into the association of COVID-19 and SPM, and COVID-19 and VTE. In the case of our patient, Covid-19 course was complicated with SPM, subcutaneous emphysema and PE/DVT. Hence, a sudden deterioration in lung function in patients with COVID-19 pneumonia, even in those without common predisposing factors or exposure to PPV, and with or without co-existing VTE, may be due to PM, and early imaging diagnosis and multidisciplinary team interventions are required to improve patient's outcome.

### Sources of financial support

None.

Q2

### Conflict of interest

The authors report no conflict of interest.

### Acknowledgment

Stephen Cattaneo, Ellen Yang, Aimee Y.Yu, Westley Hartley.

### References

Q3

1. Wang C, Horby PW, Hayden FG, Gao GF. A novel coronavirus outbreak of global health concern. *Lancet*. 2020; 395(10223):470–473.
2. Huang C, Wang Y, Li X, et al. Clinical features of patients infected with 2019 novel coronavirus in Wuhan, China. *Lancet*. 2020;395(10223):497–506.
3. Open database. WHO coronavirus disease 2019 (Covid-19) dashboard. Cited on 01/22/2021. Available from: <https://covid19.who.int/>.
4. Yang W, Kandula S, Huynh M, et al. Estimating the infection-fatality risk of SARS-CoV-2 in New York City during the spring 2020 pandemic wave: a model-based analysis. *Lancet Infect Dis*. 2021;21(2):203–212.
5. Beigel JH, Tomashek KM, Dodd LE, et al. Remdesivir for the treatment of covid-19 - final report. *N Engl J Med*. 2020;383(19): 1813–1826.
6. Rubin D, Chan-Tack K, Farley J, Sherwat A. FDA approval of remdesivir - a step in the right direction. *N Engl J Med*. 2020; 383(27):2598–2600.
7. The RECOVERY Collaborative Group. Dexamethasone in hospitalized patients with Covid-19. *N Engl J Med*. 2021;384: 693–704.
8. Stokes EK, Zambrano LD, Anderson KN, et al. *Coronavirus disease 2019 case surveillance United States, January 22-May 30*. 2020.
9. Chow N, Fleming-Dutra K, Gierke R, et al. *Preliminary estimates of the prevalence of selected underlying health conditions among patients with coronavirus disease 2019 - United States, February 12-March 28*. 2020.
10. Wang J, Su X, Zhang T, Zheng C. Spontaneous pneumomediastinum: a probable unusual complication of coronavirus disease 2019 (COVID-19) pneumonia. *Korean J Radiol*. 2020;21(5):627–628.

11. Mohan V, Tauseen RA. Spontaneous pneumomediastinum in COVID-19. *BMJ Case Rep.* 2020;13(5), e236519.
12. Mimouni H, Diyas S, Ouachaou J, et al. Spontaneous pneumomediastinum associated with COVID-19 pneumonia. *Case Rep Med.* 2020;2020:4969486.
13. Al-Azzawi M, Douedi S, Alshami A, Al-Saoudi G, Mikhail J. Spontaneous subcutaneous emphysema and pneumomediastinum in COVID-19 patients. An indicator of poor prognosis? *Am J Case Rep.* 2020;21, e925557.
14. Goldman N, Ketheeswaran B, Wilson H. COVID-19-associated pneumomediastinum. *Clin Med (Lond).* 2020;20(4): e91–e92.
15. Pooni R, Pandey G, Akbar. Broadening the differential: pneumomediastinum and COVID-19 infection. *BMJ Case Rep.* 2020;13(8), e23793.
16. Wegner U, Jeffery G, Abrajan O, Sampablo I, Singh C. Spontaneous pneumomediastinum associated with SARS-CoV-2: infrequent complication of the novel disease. *Cureus.* 2020;12(7), e9189.
17. Manna S, Maron SZ, Cedillo MA, et al. Spontaneous subcutaneous emphysema and pneumomediastinum in non-intubated patients with COVID-19. *Clin Imag.* 2020;67:207–213.
18. Vazzana N, Ognibene S, Dipaola F. Pneumomediastinum and subcutaneous emphysema after noninvasive ventilation in a COVID-19 patient. *Adv Respir Med.* 2020;88(5):466–467.
19. Colmenero V, Gallego de Guzmán P, De La Torre M. Spontaneous pneumothorax and pneumomediastinum in bilateral pneumonia due to COVID-19. *Med Intensiva.* 2020;44(9): 591–592.
20. Sun R, Liu H, Wang X. Mediastinal emphysema, giant Bulla, and pneumothorax developed during the course of COVID-19 pneumonia. *Korean J Radiol.* 2020;21(5):541–544.
21. Gillespie M, Dincher N, Fazio P, Okorji O, Finkle J, Can A. Coronavirus disease 2019 (COVID-19) complicated by spontaneous pneumomediastinum and pneumothorax. *Respir Med Case Rep.* 2020;31:101232.
22. Hazariwala V, Hadid H, Kirsch D, Big C. Spontaneous pneumomediastinum, pneumopericardium, pneumothorax and subcutaneous emphysema in patients with COVID-19 pneumonia, a case report. *J Cardiothorac Surg.* 2020;15(1):301.
23. Sahu KK, Mishra AK, Goldman Y. A rare case of Pneumopericardium secondary to COVID-19. *Heart Lung.* 2020;49(6): 679–680.
24. Loffi M, Regazzoni V, Sergio P, et al. Spontaneous pneumomediastinum in COVID-19 pneumonia. *Monaldi Arch Chest Dis.* 2020;29(4):90.
25. Underner M, Peiffer G, Perriot J, Jaafari N. Spontaneous pneumomediastinum: a rare complication of COVID-19. *Rev Mal Respir.* 2020;37(8):680–683.
26. Janssen J, Kamps MJA, Joosten TMB, Barten DG. Spontaneous pneumomediastinum in a male adult with COVID-19 pneumonia. *Am J Emerg Med.* 2020;S0735–6757(20): 30661–30666.
27. Kolani S, Houari N, Haloua M, et al. Spontaneous pneumomediastinum occurring in the SARS-COV-2 infection. *IDCases.* 2020;21, e00806.
28. Lei P, Mao J, Wang P. Spontaneous pneumomediastinum in a patient with coronavirus disease 2019 pneumonia and the possible underlying mechanism. *Korean J Radiol.* 2020;21(7): 929–930.
29. Diaz A, Patel D, Sayedy N, Anjum F. COVID-19 and Spontaneous Pneumomediastinum: a case series. *Heart Lung.* 2020; 50(2):202–205.
30. Urigo C, Soim S, Sahu A. Spontaneous pneumomediastinum as a complication of a COVID-19 related pneumonia: case report and review of literature. *Radiol Case Rep.* 2020;(12): 2577–2581.
31. Romano N, Fischetti A, Melani EF. Pneumomediastinum related to covid-19 pneumonia. *Am J Med Sci.* 2020;360(6): e19–e20.
32. Nobre Pereira M, Blanco R, Areias V. Pneumomediastinum: an uncommon complication of COVID-19 pneumonia. *Arch Bronconeumol.* 2020;S0300–2896(20):30291–X.
33. Kong N, Gao C, Xu MS, Xie YL, Zhou CY. Spontaneous pneumomediastinum in an elderly COVID-19 patient: a case report. *World J Clin Cases.* 2020;8(16):3573–3577.
34. Lacroix M, Graess F, Monnier-Cholley L, Arrivé L. SARS-CoV-2 pulmonary infection revealed by subcutaneous emphysema and pneumomediastinum. *Intensive Care Med.* 2020;46(8):1620–1621.
35. Zhou C, Gao C, Xie Y, Xu M. COVID-19 with spontaneous pneumomediastinum. *Lancet Infect Dis.* 2020;20(4):510.
36. Bellini D, Lichtner M, Vicini S, Rengo M, Ambrogi C, Carbone I. Spontaneous pneumomediastinum as the only CT finding in an asymptomatic adolescent positive for COVID-19. *BJR Case Rep.* 2020;6(3):20200051.
37. Wang W, Gao R, Zheng Y, Jiang L. COVID-19 with spontaneous pneumothorax, pneumomediastinum and subcutaneous emphysema. *J Trav Med.* 2020;27(5), taaa062.
38. López Vega JM, Parra Gordo ML, Díez Tascón A, Ossaba Vélez S. Pneumomediastinum and spontaneous pneumothorax as an extrapulmonary complication of COVID-19 disease. *Emerg Radiol.* 2020;27(6):727–730.
39. Quincho-Lopez A, Quincho-Lopez DL, Hurtado-Medina FD. Case report: pneumothorax and pneumomediastinum as uncommon complications of COVID-19 pneumonia-literature review. *Am J Trop Med Hyg.* 2020;103(3):1170–1176.
40. Shan S, Guangming L, Wei L, Xuedong Y. Spontaneous pneumomediastinum, pneumothorax and subcutaneous emphysema in COVID-19: case report and literature review. *Rev Inst Med Trop Sao Paulo.* 2020;62:e76.
41. Brogna B, Bignardi E, Salvatore P, et al. Unusual presentations of COVID-19 pneumonia on CT scans with spontaneous pneumomediastinum and loculated pneumothorax: a report of two cases and a review of the literature. *Heart Lung.* 2020;49(6):864–868.
42. Oye M, Ali A, Kandah F, Chowdhury N. Two cases of spontaneous pneumomediastinum with pneumothorax in patients with COVID-19 associated pneumonia. *Respir Med Case Rep.* 2020;31:101308.
43. Zayet S, Klopfenstein T, Mezher C, Gendrin V, Conrozier T, Ben Abdallah Y. Coronavirus disease 2019 with spontaneous pneumothorax, pneumomediastinum and subcutaneous emphysema. *France New Microbes New Infect.* 2020; 38:100785.
44. Tucker L, Patel S, Vatsis C, et al. Pneumothorax and pneumomediastinum secondary to COVID-19 disease unrelated to mechanical ventilation. *Case Rep Crit Care.* 2020;23(2020): 6655428.
45. Sonia F, Kumar M. A complication of pneumothorax and pneumomediastinum in a non-intubated patient with COVID-19: a case report. *Cureus.* 2020;12(8), e10044.
46. Eperjesiova B, Hart E, Shokr M, Sinha P, Ferguson GT. Spontaneous pneumomediastinum/pneumothorax in patients with COVID-19. *Cureus.* 2020;12(7), e8996.
47. Singh A, Bass J, Lindner DH. Rare complication of pneumomediastinum and pneumopericardium in a patient with COVID-19 pneumonia. *Case Rep Pulmonol.* 2020;2020: 8845256.
48. Grewal S, Harjo B, Aykut G, et al. Case report: sublingual microcirculatory alterations in a covid-19 patient with subcutaneous emphysema, venous thrombosis, and pneumomediastinum. *Front Med.* 2021;7:624695.
49. Marsico S, Del Carpio Bellido LA, Zuccarino F. Spontaneous pneumomediastinum and macklin effect in COVID-19 patients. *Arch Bronconeumol.* 2020;S0300–2896(20):30265–30269.
50. Yellin A, Gapany-Gapanavicius M, Lieberman Y. Spontaneous pneumomediastinum: is it a rare cause of chest pain? *Thorax.* 1983;38(5):383–385.
51. Dekel B, Paret G, Szeinberg A, Vardi A, Barzilay Z Spontaneous pneumomediastinum in children: clinical and natural history. *Eur J Pediatr.* 1996;155(8):695–697.
52. Gu J, Korteweg C. Pathology and pathogenesis of severe acute respiratory syndrome. *Am J Pathol.* 2007;170(4):1136–1147.
53. Jougon JB, Ballester M, Delcambre F, Mac Bride T, Dromer CE, Velly JF. Assessment of spontaneous

pneumomediastinum: experience with 12 patients. *Ann Thorac Surg.* 2003;75(6):1711–1714.

54. Panigada M, Bottino N, Tagliabue P, et al. Hypercoagulability of COVID-19 patients in intensive care unit: a report of thromboelastography findings and other parameters of hemostasis. *J Thromb Haemostasis.* 2020;18:1738.
55. Maier CL, Truong AD, Auld SC, et al. COVID-19-associated hyperviscosity: a link between inflammation and thrombophilia? *Lancet.* 2020;395:1758.
56. Connors JM, Levy JH. Thromboinflammation and the hypercoagulability of COVID-19. *J Thromb Haemostasis.* 2020;18:1559.
57. Helms J, Tacquard C, Severac F, et al. High risk of thrombosis in patients with severe SARS-CoV-2 infection: a multicenter prospective cohort study. *Intensive Care Med.* 2020;46:1089.
58. Bilaloglu S, Aphinyanaphongs Y, Jones S, et al. Thrombosis in hospitalized patients with COVID-19 in a New York city health System. *JAMA.* 2020;324:799.

**AUTHOR QUERY FORM**

 <b>ELSEVIER</b>	<b>Journal: JCHIMP</b>  <b>Article Number: 1002</b>	
------------------------------------------------------------------------------------------------------	-----------------------------------------------------------	--

Dear Author,

Please check your proof carefully and mark all corrections at the appropriate place in the proof (e.g., by using on-screen annotation in the PDF file) or compile them in a separate list. **It is crucial that you NOT make direct edits to the PDF using the editing tools as doing so could lead us to overlook your desired changes.** Note: if you opt to annotate the file with software other than Adobe Reader then please also highlight the appropriate place in the PDF file. To ensure fast publication of your paper please return your corrections within 48 hours.

For correction or revision of any artwork, please consult <http://www.elsevier.com/artworkinstructions>.

Any queries or remarks that have arisen during the processing of your manuscript are listed below and highlighted by flags in the proof.

<b>Location in article</b>	<b>Query / Remark: Click on the Q link to find the query's location in text Please insert your reply or correction at the corresponding line in the proof</b>
<b>Q1</b>	Please provide History dates [Received, Revised and Accepted dates].
<b>Q2</b>	Correctly acknowledging the primary funders and grant IDs of your research is important to ensure compliance with funder policies. Please make sure that funders are mentioned accordingly.
<b>Q3</b>	Please note that Refs [14] and [29] were identical, and Ref. [29] has been deleted. The subsequent references have been renumbered.
<b>Q4</b>	Please confirm that given names and surnames have been identified correctly and are presented in the desired order and please carefully verify the spelling of all authors' names. <div data-bbox="304 1378 895 1555" style="border: 1px solid black; padding: 5px; margin-top: 10px;"> <p style="color: red;">Please check this box or indicate your approval if you have no corrections to make to the PDF file</p> <div style="text-align: right; margin-right: 20px;"> <input data-bbox="791 1438 876 1519" type="checkbox"/> </div> </div>

Thank you for your assistance.