

2022

## COVID-19 and Aortic Thrombosis: A Case Report

Mamtha Balla

*Clinical Assistant Professor, Department of Internal Medicine, University of Toledo and Promedica Toledo Hospital, Toledo, Ohio 43606, United States, athamam@gmail.com*

Hannah Staats-Ciotola

*Department of Internal Medicine, University of Toledo College of Medicine & Life Sciences, Toledo, OH 43614, U.S.A*

Meera Dhavale

*Department of Internal Medicine, S.D.M. Medical College, India*

Vikram Sangani

*Hospitalist, Department of Internal Medicine, Navicent Health, Macon , Georgia 31201.*

Mytri Pokal

*Hospitalist, Department of Internal Medicine, Navicent Health, Macon, Georgia 31201.*

*See next page for additional authors*

Follow this and additional works at: <https://scholarlycommons.gbmc.org/jchimp>

---

### Recommended Citation

Balla, Mamtha; Staats-Ciotola, Hannah; Dhavale, Meera; Sangani, Vikram; Pokal, Mytri; Merugu, Ganesh Prasad; Konala, Venu Madhav; Adapa, Sreedhar; Naramala, Srikanth; and Rallabhandi, Sai Sri Harsha (2022) "COVID-19 and Aortic Thrombosis: A Case Report," *Journal of Community Hospital Internal Medicine Perspectives*: Vol. 12: Iss. 3, Article 19.

DOI: 10.55729/2000-9666.1060

Available at: <https://scholarlycommons.gbmc.org/jchimp/vol12/iss3/19>

This Case Report is brought to you for free and open access by the Journal at GBMC Healthcare Scholarly Commons. It has been accepted for inclusion in Journal of Community Hospital Internal Medicine Perspectives by an authorized editor of GBMC Healthcare Scholarly Commons. For more information, please contact [GBMCcommons@gbmc.org](mailto:GBMCcommons@gbmc.org).

---

## COVID-19 and Aortic Thrombosis: A Case Report

### Authors

Mamtha Balla, Hannah Staats-Ciotola, Meera Dhavale, Vikram Sangani, Mytri Pokal, Ganesh Prasad Merugu, Venu Madhav Konala, Sreedhar Adapa, Srikanth Naramala, and Sai Sri Harsha Rallabhandi

# COVID-19 and Aortic Thrombosis: A Case Report

Mamtha Balla <sup>a,\*</sup>, Hannah Staats-Ciotola <sup>b</sup>, Meera Dhavale <sup>c</sup>, Vikram Sangani <sup>d</sup>, Mytri Pokal <sup>d</sup>, Ganesh Prasad Merugu <sup>e</sup>, Venu Madhav Konala <sup>f</sup>, Sreedhar Adapa <sup>g</sup>, Srikanth Naramala <sup>h</sup>, Sai Sri Harsha Rallabhandi <sup>i</sup>

<sup>a</sup> Department of Internal Medicine, University of Toledo and Promedica Toledo Hospital, Toledo, OH 43606, USA

<sup>b</sup> Department of Internal Medicine, University of Toledo College of Medicine & Life Sciences, Toledo, OH 43614, USA

<sup>c</sup> Department of Internal Medicine, S.D.M. Medical College, India

<sup>d</sup> Hospitalist, Department of Internal Medicine, Navicent Health, Macon GA, 31201, USA

<sup>e</sup> Division Chief and Geriatric Fellowship Program Director, Division of Geriatric Medicine, Department of Family Medicine, University of Toledo, OH, 43614, USA

<sup>f</sup> Department of Internal Medicine, Division of Medical Oncology, Precision Cancer Center, 122 St Christopher Dr, Ashland, KY 41169, USA

<sup>g</sup> Department of Internal Medicine, Division of Nephrology, Adventist Medical Center, Hanford, CA 93230, USA

<sup>h</sup> Department of Internal Medicine, Division of Rheumatology, Adventist Medical Center, Hanford, CA 93230, USA

<sup>i</sup> Department of Internal Medicine, Gandhi Medical College, India

## Abstract

Coronavirus disease 2019 (COVID-19) is an infection caused by severe acute respiratory syndrome coronavirus 2 (SARS-CoV-2). It is known to cause a myriad of symptoms ranging from mild respiratory illness to severe pneumonia and acute respiratory distress. Since its discovery in late 2019 in Wuhan, China, the virus has caused a devastating worldwide pandemic. Although COVID-19 most commonly causes respiratory symptoms, complications such as hypercoagulability are now known to occur in some patients. In this case report, we present a COVID-19 patient that suffered a stroke and was found to have an aortic thrombus. In this case report, we discussed hypercoagulability, venous and arterial thrombosis in COVID-19 patients. We hope to highlight the importance of monitoring laboratory markers of hypercoagulability and thromboembolism symptoms in COVID-19 patients and encourage appropriate prophylaxis and treatment with anticoagulants when necessary. It is unclear whether or not a causal relationship exists given the nature of the syndrome. However, given the growing number of reported cases physicians should maintain awareness of this possible complication when evaluating COVID-19 patients.

**Keywords:** Covid- 19, Complications of COVID-19, Aortic thrombus

## 1. Introduction

As of July, 21, 2021, there have been 191,148,056 confirmed cases and 4,109,303 deaths from COVID-19 globally, out of which 33,828,878 cases and 604,252 deaths were in the United States alone.<sup>1</sup> Thousands of new cases continue to be reported daily, even with the widespread vaccination campaign administered over 55 million doses in the United States.<sup>2</sup> In addition to receiving the vaccination, other preventive techniques continue to be highly recommended. These include frequent

handwashing, avoiding touching of the eyes, nose, mouth, social distancing of six feet between people not from the same household, avoiding contact with sick individuals, wearing a mask around others, and daily cleaning of frequently touched surfaces.<sup>3</sup> Over the last one and a half years since the emergence of the virus in December 2019, clinicians continue to discover new things about the natural course of COVID-19. One of the complications that COVID-19 is now known to cause is a hypercoagulable state with an increased risk of thromboembolism.<sup>4</sup> Therefore, clinicians must keep an eye out for this

Received 22 July 2021; revised 11 November 2021; accepted 19 November 2021.  
Available online 2 May 2022.

\* Corresponding author at: Department of Internal Medicine, University of Toledo, Promedica Toledo Hospital Toledo, Ohio, 43606, USA.  
E-mail addresses: [athamam@gmail.com](mailto:athamam@gmail.com) (M. Balla), [hannah.staats@rockets.utoledo.edu](mailto:hannah.staats@rockets.utoledo.edu) (H. Staats-Ciotola), [meera.dhavale@gmail.com](mailto:meera.dhavale@gmail.com) (M. Dhavale), [docvikramsangani@gmail.com](mailto:docvikramsangani@gmail.com) (V. Sangani), [mythripokal@gmail.com](mailto:mythripokal@gmail.com) (M. Pokal), [Ganesh.merugu@utoledo.edu](mailto:Ganesh.merugu@utoledo.edu) (G.P. Merugu), [drvenumadhav@gmail.com](mailto:drvenumadhav@gmail.com) (V.M. Konala), [sreedharadapa@gmail.com](mailto:sreedharadapa@gmail.com) (S. Adapa), [dr.srikanth83@gmail.com](mailto:dr.srikanth83@gmail.com) (S. Naramala), [Sriharsha296@gmail.com](mailto:Sriharsha296@gmail.com) (S.S. Harsha Rallabhandi).

<https://doi.org/10.55729/2000-9666.1060>

2000-9666/© 2022 Greater Baltimore Medical Center. This is an open access article under the CC BY-NC license (<http://creativecommons.org/licenses/by-nc/4.0/>).

complication while managing a COVID-19 patient, especially if they are at high risk for thrombosis or when new physical exam findings or symptoms arise.

## 2. Patient presentation

An 83-year-old female with a past medical history of hypertension, type two diabetes mellitus, hyperlipidemia, and stroke presented to the emergency department with altered mental status. She was conversational and alert but oriented only to herself. Her son reported that she had been acting confused before admission. On initial examination, she was found to have a temperature of 39.3 °C, heart rate of 107, respiratory rate of 27, BP 156/97, and oxygen saturation of 91% at room air. In the Emergency Room (E.R.), the patient was noted to be in atrial fibrillation on the cardiac monitor. On physical examination, the patient appears to be non-toxic and in no acute distress. Alert and oriented x1 but pleasant and conversational. Cardiovascular examination showed Irregular rhythm and tachycardic. S1 and S2 appreciated. No jugular venous dilation. On respiratory examination scattered crackles were noted. On neurological examination motor strength and sensation symmetric throughout. Refer to [Table 1](#) for a summary of laboratory results upon admission. Computed tomography (C.T.) chest without contrast revealed bilateral multifocal opacities with imaging features typical for COVID-19 infection. Polymerase chain reaction (PCR) test confirmed the COVID-19 infection. She was started on Lovenox 90 mg subcutaneous injections twice a day due to the paroxysmal atrial fibrillation. Her home medications included

aspirin 81 mg, atorvastatin 80 mg, carvedilol, amlodipine, famotidine, and insulin lispro sliding scale. On her second day of hospitalization, she was alert, oriented to time, place, and person, and answered questions coherently ([Table 2](#)). She had returned to her baseline mentation, confirmed by her son via phone call. During the morning of day three of hospitalization, she was found to be in sinus rhythm, so her Lovenox was discontinued, and Eliquis 5 mg twice a day was started. On day seven, the patient started requiring oxygen therapy via nasal cannula, and a chest x-ray revealed worsening infiltrates. Due to concerns of hospital-acquired pneumonia, she was started on vancomycin and Zosyn. On day nine, the patient's mental status drastically changed; she was significantly more confused and lethargic but arousable. She was nonverbal and unable to follow commands or vocalize understanding. Neurological examination was positive for subtle right facial asymmetry and droop, right arm flaccidity, with sensation to pain upon deep stimulation. She could not overcome gravity with her right upper or lower extremities but did withdraw to pain. A stroke alert was called. Repeat D-dimer was 1337 ng/mL DDU (normal <255 ng/mL DDU). CT scan of the brain without contrast showed no evidence of intracranial hemorrhage or acute pathology. Severe small vessels ischemic change in the deep white matter supratentorial and cortical atrophy no other significant interval change from previous C.T. scan of the brain done upon admission. She had a National Institutes of Health Stroke Scale of 18. C.T. angiogram of the head showed no evidence of large vessel intracranial occlusion, but it showed irregularity and

*Table 1. Summary of laboratory abnormalities.*

Laboratory findings	Patient's value (normal values)
White blood cell count	4.7 (4.0–11.0 X10E9/L)
Lymphocytes absolute (low)	0.8 (1.0–3.5 X10E9/L)
Potassium (low)	3.4 (3.5–5.0 mmol/L)
Creatinine (high)	1.19 (0.40–1.00 mg/dL)
Glucose (high)	202 (65–99 mg/dL)
Aspartate aminotransferase (high)	60 (0–41 U/L)
Alanine aminotransferase (high)	38 (0–31 U/L)
Procalcitonin (high)	0.13 (<0.05 ng/mL)
D-dimer (high)	1439 (<255 ng/mL DDU)
C-reactive protein (high)	4.6 (0.000–0.744 mg/dL)
Lactate (high)	3.1 (0.4–2.0 mmol/L)
Erythrocyte sedimentation rate (high)	73 (0–30 mm/h)
Ammonia (high)	60 (11–35 umol/L)
Portable troponin	0.07 (0.00–0.09 ng/mL)
B-type natriuretic peptide (high)	178 (<100.0 pg/mL)
Myoglobin, serum (high)	107.7 (14.3–65.8 ng/mL)
International normalized ratio	1.1 (0.8–1.1)
Activated partial thromboplastin time (low)	24 (26–37 s)
Body Mass Index	31.85 kg/m <sup>2</sup>

Table 2. Summary of Patient's mental status throughout hospitalization.

Day of Admission	Patient's Mental Status
1 (At presentation)	Conversational but alert and oriented only to herself, she had been acting confused per her son.
2	Alert, oriented to time, place, and person, and answered questions properly. She had returned to her baseline mentation, confirmed by her son via phone call.
9	The patient's mental status drastically changed; she was significantly more confused and lethargic but arousable. She was nonverbal and unable to follow commands or vocalize understanding. Neurological examination was positive for subtle right facial asymmetry and droop, right arm flaccidity with sensation to pain upon deep stimulation. She could not overcome gravity with her right upper or lower extremities but did withdraw to pain. National Institutes of Health Stroke Scale (NIHSS) of 18.
17 (Discharge)	Answered yes and no questions, but her comprehension and mental status were still impaired. She continued to have aphasia and right-sided weakness.

narrowing of the anterior cerebral artery's distal branches. C.T. angiogram of the chest showed a mural thrombus in the distal aortic arch extending into the descending aorta consistent with prior dissection, as shown in Figs. 1 and 2. The brain's M.R.I. without contrast showed moderate-sized acute/subacute ischemic infarction at the left frontal lobe's medial aspect along with the left anterior cerebral artery distribution. At this time, nurses shared that the nursing aides noticed that the patient had been spitting out her medications, and they were not sure if she had been receiving all her medications. Eliquis was discontinued, and a heparin drip was started. Routine electroencephalogram showed left frontal-temporal dysfunction with evidence of right temporal cortical dysfunction and moderate diffuse encephalopathy; no epileptiform discharges or seizures were seen. She was transitioned to Coumadin as per agreement of vascular surgery and cardiothoracic surgery. On day seventeen of admission, the patient was discharged to a skilled nursing facility on Coumadin with the

instructions to follow-up with vascular surgery to evaluate the need for further surgery. On discharge, she answered yes and no questions, but her comprehension and mental status were still impaired. She continued to have aphasia and right-sided weakness.

### 3. Discussion

This patient had many risk factors for stroke upon admission. In addition to the presence of atrial fibrillation, her history of stroke, type two diabetes mellitus, and hypertension with her age and gender make her CHA<sub>2</sub>DS<sub>2</sub>-Vasc score 7. This score put her at moderate-high risk for stroke and made her a candidate for anticoagulation. In addition to this risk, our patient had a COVID-19 infection, which is known to cause hypercoagulability. The hypercoagulable state mechanism in a patient with COVID-19 is thought to be due to endothelial damage via direct invasion, cytokine release, and the activation of complement pathways; stasis; and hypercoagulable

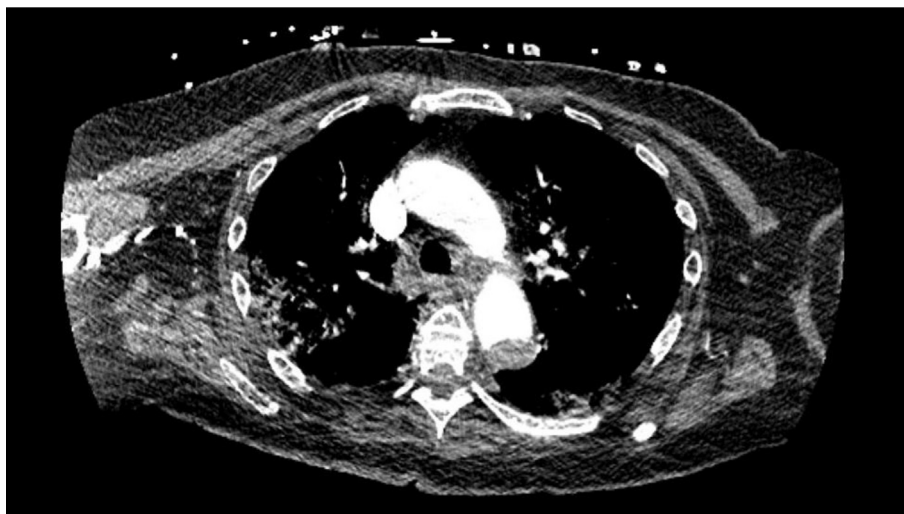


Fig. 1. Axial Section of the chest CT showing Aortic thrombus.

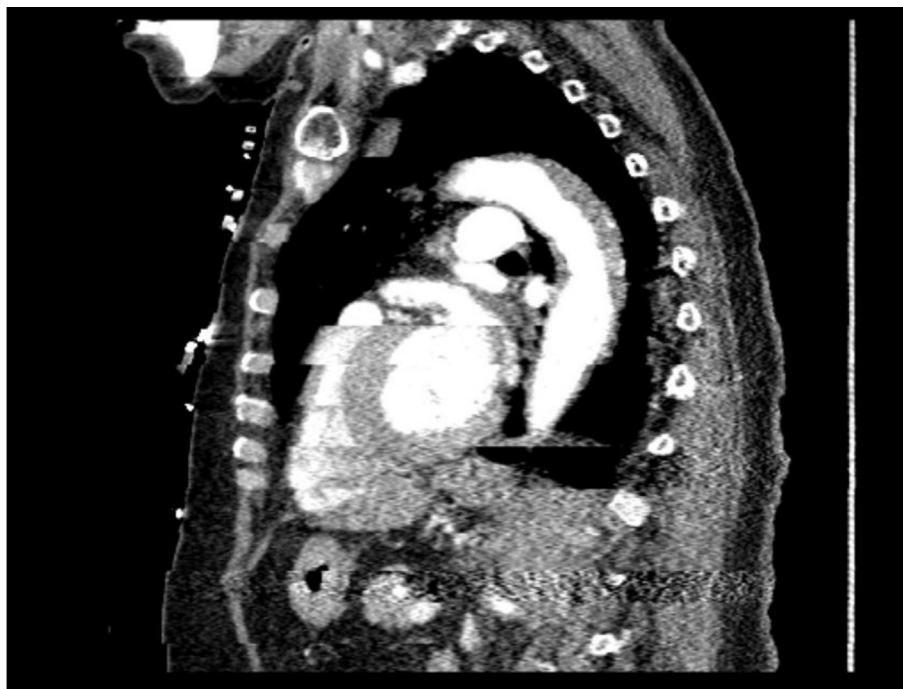

Fig. 2. Sagittal view of the chest CT showing extension of the aortic thrombus.

state via increased prothrombotic factors.<sup>5</sup> A report published by Panigada et al. provides evidence that supports the theory of increased prothrombotic factors in patients with COVID-19. They observed a series of patients admitted to the intensive care unit whose lab parameters were consistent with a state of hypercoagulability. These patients were found to have normal or increased platelet counts, along with an increase in fibrinogen, D-dimer, C-reactive protein, factor VIII, von Willebrand factor, and protein C marginally decreased antithrombin<sup>6</sup>. As a result of this hypercoagulable state, the incidence of venous and arterial thromboembolism increases during COVID-19,<sup>7</sup> further increasing the mortality in these patients. The presence of thrombosis and microangiopathy in the lungs' small vessels and capillaries has been reported in multiple autopsies performed on patients who died of COVID-19.<sup>8</sup>

A study involving 1114 COVID-19 patients at Mass General Brigham integrated health network analyzed the incidence of arterial and venous thromboembolism and their effects on patients managed in intensive care ( $n = 170$ ), hospitalized non-intensive care ( $n = 229$ ), and outpatient ( $n = 715$ ) settings. They found major arterial or venous thromboembolism, major cardiovascular adverse events, and symptomatic venous thromboembolism were highest in the intensive care group (35.3%, 45.9%, 27.0%, respectively). Whereas hospitalized

non-intensive care group had 2.6%, 6.1%, and 2.2%, respectively, and 0% occurrence in the outpatient group. Prophylactic anticoagulation was given to 89.4% of the intensive care group and 84.7% of the hospitalized non-intensive care group, suggesting that coagulopathy is common among COVID-19 patients with more severe infections.<sup>9</sup>

Arterial thromboembolism in patients with COVID-19 is not as well documented in literature as venous thromboembolism. Arterial thrombosis most commonly causes myocardial infarction, stroke, and limb ischemia. In a review performed by Cheruiyot et al., they assessed 27 studies (5 cohort studies, 5 case series, and 17 case reports) that reported arterial thrombotic events in patients with COVID-19. Arterial thromboembolism in critically ill patients treated in intensive care units was 4.4% in the five cohort studies. These events were symptomatic in over 95% of those patients and involved multiple arteries in 18%. The most commonly involved arteries were limb arteries (39%), cerebral arteries (24%), great vessels including the aorta, common iliac, common carotid, and brachiocephalic trunk (19%), coronary arteries (9%), and the superior mesenteric artery (8%). A mortality rate of approximately 20% was reported in these patients.<sup>10</sup> Table 3 gives a brief account of similar case reports that chronicle the occurrences of arterial thromboembolism in patients with COVID-19.

Table 3. Locations of arterial thromboembolic events in four COVID-19 case reports.

Study	Number of Patient Cases	Arterial Locations of Thromboembolic Event
Levolger et al. <sup>11</sup>	4	Common iliac artery, tibial-fibular trunk, subclavian artery, internal carotid, and superior mesenteric artery
Singh et al. <sup>12</sup>	3	Tibial artery, aorta, popliteal artery, common iliac artery, and left ventricle apex
Lushina et al. <sup>13</sup>	1	Distal basilar artery and renal artery
Kashi et al. <sup>14</sup>	7	Aorta, popliteal artery, common femoral artery, iliac artery, deep femoral artery, and femoropopliteal bypass

Table 4. Locations of aortic thrombosis in eight case reports.

Study	Number of Patient Cases	Aortic Location of Thrombosis (number of patients) <sup>a</sup>
Kashi et al. <sup>14</sup>	2	Descending aorta (2), aortic arch (1)
de Carranza et al. <sup>15</sup>	3	Aortic arch (1), ascending aorta (1), descending aorta (2)
Baeza et al. <sup>16</sup>	3	Abdominal aorta with extension to both iliac arteries (3)
Mukherjee et al. <sup>17</sup>	1	Ascending aorta (1)
Gomez-Arbelaez et al. <sup>18</sup>	4	Aortoiliac (2), aortic arch (1), descending thoracic aorta (1)
Woehl et al. <sup>19</sup>	4	Descending aorta (1), abdominal aorta (1), abdominal aortic with extension to both iliac arteries (1), abdominal aorta with extension to the right iliac artery (1)
Katchanov et al. <sup>20</sup>	1	Lower thoracic aorta with extension to the abdominal aorta and both iliac arteries (1)
Wickham et al. <sup>21</sup>	1	Lower thoracic aorta (1)

<sup>a</sup> Some patients had a thrombosis in multiple locations.

In our patient, we see an example of arterial thrombosis in the aortic arch extending into the descending aorta. Although the aorta is not a typical location to experience thrombotic disease, due to the hypercoagulability of COVID-19, it is fairly common to find thrombi in atypical locations. We reviewed eight articles that described 19 cases involving aortic thrombosis in COVID-19 patients. Table 4 summarizes the locations of thrombosis within the aorta as reported in these case studies.<sup>14–21</sup> Of the 19 cases, three patients experienced a stroke, nine experienced acute limb ischemia, two experienced acute mesenteric ischemia, two experienced acute kidney infarction, some patients had more than one complication, and five patients were asymptomatic. There is enough evidence to prove that aortic thrombosis can have diverse presentations, ranging from asymptomatic to severe and life-threatening complications. Although this pathology is usually considered rare, it needs to be kept in mind when treating COVID-19 patients for prevention or early intervention of these complications.

#### 4. Conclusion

Reflecting on our case report and the information we gathered, we know that a delayed diagnosis makes arterial thrombosis a lethal complication in COVID-19 patients. Since vigilant monitoring of symptoms and procoagulant labs, and timely intervention prevents thromboembolic complications in patients, it is important to keep an eye out for these

to reduce morbidity and mortality. Since imaging has a potential role in screening and early diagnosis of thromboembolism in COVID-19 patients, imaging frequency should be individualized for the patients based on a risk-benefit analysis. Additionally, more research needs to be conducted to assess the best level and type of anticoagulation used in COVID-19 patients based on the risk factors and severity of the disease. It is important to note an increased incidence of confusion associated with the COVID-19 patient population, especially in those with increased isolation status. Hence, it would be useful to use anticoagulants whose serum levels can be monitored, such as warfarin instead of Eliquis or Xarelto. COVID-19 is still a relatively new disease and continues to be elusive in its presentation and course. Newer complications and difficulties with management emerge every day. Persistent observation, research, and reflection from all of us would help improve patient care.

#### Financial disclosure

None.

#### Informed consent

Obtained.

#### Author contributions

M.B., VMK, SN, SA, VS and G.P.M. assisted in conceptualization and data. M.B., H.S. and M.D.

helped in curation, analysis, writing, revision, and editing; M.P., MB, SSHR, G.P.M. assisted in investigation, writing, revision, and editing; M.B. assisted in data curation, writing, editing, revisions, supporting, and supervision.

### Data availability

From the patient's chart and PUB MED, google scholar.

### Conflict of interest

None.

### References

1. WHO coronavirus disease (COVID-19) dashboard. Available from: <https://covid19.who.int/>. (Accessed July 21, 2021).
2. CDC COVID data tracker. Available from: <https://covid.cdc.gov/covid-data-tracker/#vaccinations>. (Accessed July 21, 2021).
3. How to protect yourself & others. <https://www.cdc.gov/coronavirus/2019-ncov/prevent-getting-sick/prevention.html>.
4. Miesbach W, Makris M. COVID-19: coagulopathy, risk of thrombosis, and the rationale for anticoagulation. *Clin Appl Thromb Hemost*. 2020;26, 1076029620938149. <https://doi.org/10.1177/1076029620938149>.
5. Singhanian N, Bansal S, Nimmatoori DP, et al. Current overview on hypercoagulability in COVID-19. *Am J Cardiovasc Drugs*. 2020;20:393–403. <https://doi.org/10.1007/s40256-020-00431-z>.
6. Panigada M, Bottino N, Tagliabue P, et al. Hypercoagulability of COVID-19 patients in intensive care unit: a report of thromboelastography findings and other parameters hemostasis. *J Thromb Haemostasis*. 2020;18:1738–1742. <https://doi.org/10.1111/jth.14850>.
7. Klok FA, Kruip MJHA, van der Meer NJM, et al. Incidence of thrombotic complications in critically ill I.C.U. patients with COVID-19. *Thromb Res*. 2020;191:145–147. <https://doi.org/10.1016/j.thromres.2020.04.013>.
8. Fox SE, Akmatbekov A, Harbert JL, Li GM, Quincy Brown J, Vander Heide RS. Pulmonary and cardiac pathology in African American patients with COVID-19: an autopsy series from New Orleans. *Lancet Respir*. 2020;8(7):681–686. [https://doi.org/10.1016/S2213-2600\(20\)30243-5](https://doi.org/10.1016/S2213-2600(20)30243-5).
9. Piazza G, Campia U, Hurwiz S, et al. Registry of arterial and venous thromboembolic complications in patients with COVID-19. *J Am Coll Cardiol*. 2020;76(18):2060–2072. <https://doi.org/10.1016/j.jacc.2020.08.070>.
10. Cheruiyot I, Kipkorir V, Kariuki B, et al. Arterial thrombosis in coronavirus disease 2019 patients: a rapid systemic review. *Ann Vasc Surg*. 2020;70:273–281. <https://doi.org/10.1016/j.avsg.2020.08.087>.
11. Levolger S, Bokkers RPH, Wille J, Kropman RHJ, de Vries J-PPM. Arterial thrombotic complications in COVID-19 patients. *J Vasc Surg Cases Innov Tech*. 2020;6(3):454–459. <https://doi.org/10.1016/j.jvscit.2020.06.012>.
12. Singh G, Attique HB, Gadela NV, Mapara K, Manickaratnam S. COVID-19 related arterial coagulopathy. *Cureus*. 2020;12(7), e9490. <https://doi.org/10.7759/cureus.9490>.
13. Lushina N, Kuo JS, Shaikh HA. Pulmonary, cerebral, and renal thromboembolic disease in a patient with COVID-19. *Radiology*. 2020;296(3):E181–E183. <https://doi.org/10.1148/radiol.2020201623>.
14. Kashi M, Jacquin A, Dakhil B, et al. Severe arterial thrombosis associated with Covid-19 infection. *Thromb Res*. 2020;192: 75–77. <https://doi.org/10.1016/j.thromres.2020.05.025>.
15. De Carranza M, Salazar DE, Troya J, et al. Aortic thrombus in patients with severe COVID-19: a review of three cases. *J Thromb Thrombolysis*. 2021;51:237–242. <https://doi.org/10.1007/s11239-020-02219-z>.
16. Baeza C, González A, Torres P, Pizzamiglio M, Arribas A, Aparicio C. Acute aortic thrombosis in COVID-19. *J Vasc Surg Cases Innov Tech*. 2020;6(3):483–486. <https://doi.org/10.1016/j.jvscit.2020.06.013>.
17. Mukherjee A, Ghosh R, Furment MM. Case report: COVID-19 associated renal infarction and ascending aortic thrombosis. *Am J Trop Med Hyg*. 2020;103(5):1989–1992. <https://doi.org/10.4269/ajtmh.20-0869>.
18. Gomez-Arbelaez D, Ibarra-Sanchez G, Garcia-Gutierrez A, Comanges-Yeboles A, Ansuategui-Vicente M, Gonzalez-Fajardo JA. COVID-19-Related aortic thrombosis: a report of Four cases. *Ann Vasc Surg*. 2020;67:10–13. <https://doi.org/10.1016/j.avsg.2020.05.031>.
19. Woehl B, Lawson B, Lambert L, Tusch J, Ghassani A, Hamade A. 4 cases of aortic thrombosis in patients with COVID-19. *JACC Case Rep*. 2020;2(9):1397–1401. <https://doi.org/10.1016/j.jaccas.2020.06.003>.
20. Katchanov J, Kalisch J, Herzing W, et al. Extensive aortic thrombosis in a patient with COVID-19. *Ann Emerg Med*. 2020; 76(3):373–374. <https://doi.org/10.1016/j.annemergmed.2020.04.044>.
21. Wickham H, Tam JCH, Chan XHS, George MJ, Levi M, Brown M. Aortic thrombosis in COVID-19. *Clin Infect Pract*. 2020;9:100059. <https://doi.org/10.1016/j.clinpr.2020.100059>.